




Clinical Presentation and Management of Monkeypox

Dr Jacky Chan
Consultant, HAIDC

Concerning recent monkeypox outbreak outside Africa, one may wonder..



- How should we recognize the symptoms and signs of monkeypox?
- Is monkeypox a lethal disease?
- Are there specific antiviral treatments?
- Is vaccine available?

Monkeypox

- Human monkeypox is a **zoonosis** caused by monkeypox virus, an orthopoxvirus and close relative of variola virus (smallpox)
- Monkeypox was first discovered in 1958 in monkeys kept for research in the Democratic Republic of the Congo (DRC)
- First reported in humans in 1970 in the Democratic Republic of Congo, most of the reported monkeypox outbreaks have occurred in Central and West Africa



Zoonotic outbreak in the US in 2003

- In 2003, there was a zoonotic outbreak in the USA causing 47 confirmed or suspected cases
- The outbreak was linked to the importation of Gambia giant rats, squirrels, and dormice, which had transmitted the virus to prairie dogs that were then sold as pets
- Only 14 patients were hospitalized and there were no confirmed case of person-to-person transmission



Recent outbreak outside Africa

US tracks monkeypox case tied to recent Canadian travel

Filed Under: **Monkeypox**
Stephanie Soucheray | News Reporter | CIDRAP News | May 19, 2022
Share Tweet LinkedIn Email Print & PDF

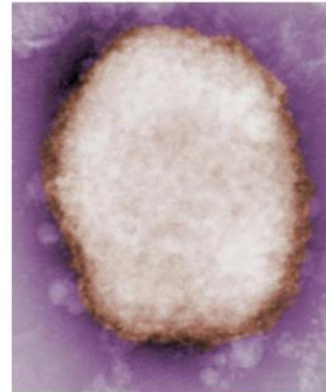
US officials have confirmed a case of monkeypox in a Massachusetts resident who had recently traveled to Canada, where health officials are **investigating 17 cases** in the Montreal area.

This is the first monkeypox case detected this year in the United States. In 2021, both **Maryland and Texas reported** single cases in residents who had recently traveled to Nigeria, where the virus is endemic.

But the current case and more than two dozen cases in Europe do not involve recent travel to endemic countries. Instead, community spread is suspected among men who have sex with men, suggesting close sexual and personal contact is behind the recent uptick in cases.

"Many of these global reports of monkeypox cases are occurring within sexual networks. However, healthcare providers should be alert to any rash that has features typical of monkeypox," said Inger Damon, MD, PhD, a poxvirus expert at the Centers for Disease Control and Prevention (CDC) in a **press release**.
"We're asking the public to contact their healthcare provider if they have a new rash and are concerned about monkeypox."

According to the CDC, monkeypox is being spread through contact with body fluids, monkeypox sores, or shared items (such as clothing and bedding) that have been contaminated with fluids or sores of a person with monkeypox.



CDC / Charles D. Humphrey; Tiara Morehead; Russell Regnery
Monkeypox virus highly magnified.

Monkeypox

22 May 2022

Public health advice for gay, bisexual and other men who have sex with men

An outbreak of a disease called **monkeypox** is currently taking place in many countries that do not typically have cases. This can be concerning, especially for people whose loved ones or community have been affected. Some cases have been identified through sexual health clinics in communities of gay, bisexual and other men who have sex with men. It is important to note that the risk of monkeypox is not limited to men who have sex with men. Anyone who has close contact with someone who is infectious is at risk. However, given that the virus is being identified in these communities, learning about monkeypox will help ensure that as few people as possible are affected and that the outbreak can be stopped.

How to use this document: This document contains information on how monkeypox spreads, what to do if you think you have symptoms and how to protect yourself and others. It can be used by community leaders, influencers, health workers and people attending social events and parties to inform and engage communities of men who have sex with men.
Information on this outbreak is changing rapidly as we learn more. Check who.int for the most up to date information.

What you need to know

- An outbreak of a disease called monkeypox is happening in some countries where the virus is not typically found. Some of these cases are being found in communities of gay, bisexual and other men who have sex with men. Transgender people and gender-diverse people may also be more vulnerable in the context of the current outbreak.
- Symptoms include:
 - Rash with blisters on face, hands, feet, eyes, mouth and/or genitals
 - Fever
 - Swollen lymph nodes
 - Headaches
 - Muscle aches
 - Low energy
- You can catch monkeypox if you have close physical contact with someone who is showing symptoms. This includes touching and being face-to-face.
- Monkeypox can spread during close skin-to-skin contact during sex, including kissing, touching, oral and penetrative sex with someone who has symptoms. Avoid having close contact with anyone who has symptoms.
- Protect yourself and others by:
 - Isolating at home and talking to a health worker if you have symptoms
 - Avoid skin-to-skin or face-to-face contact, including sexual contact with anyone who has symptoms
 - Clean hands, objects, and surfaces that have been touched regularly
 - Wear a mask if you are in close contact with someone with symptoms

Stigmatising people because of a disease is never ok.
Anyone can get or pass on monkeypox, regardless of their sexuality.

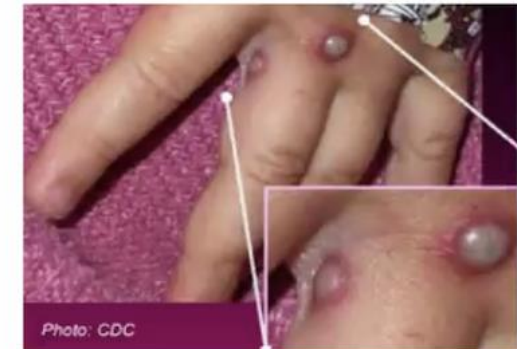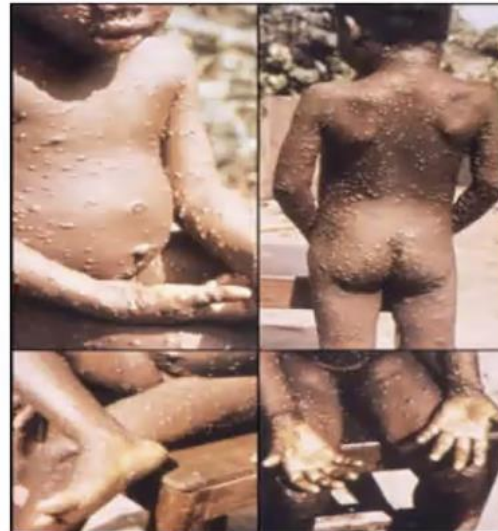<https://www.cidrap.umn.edu/>

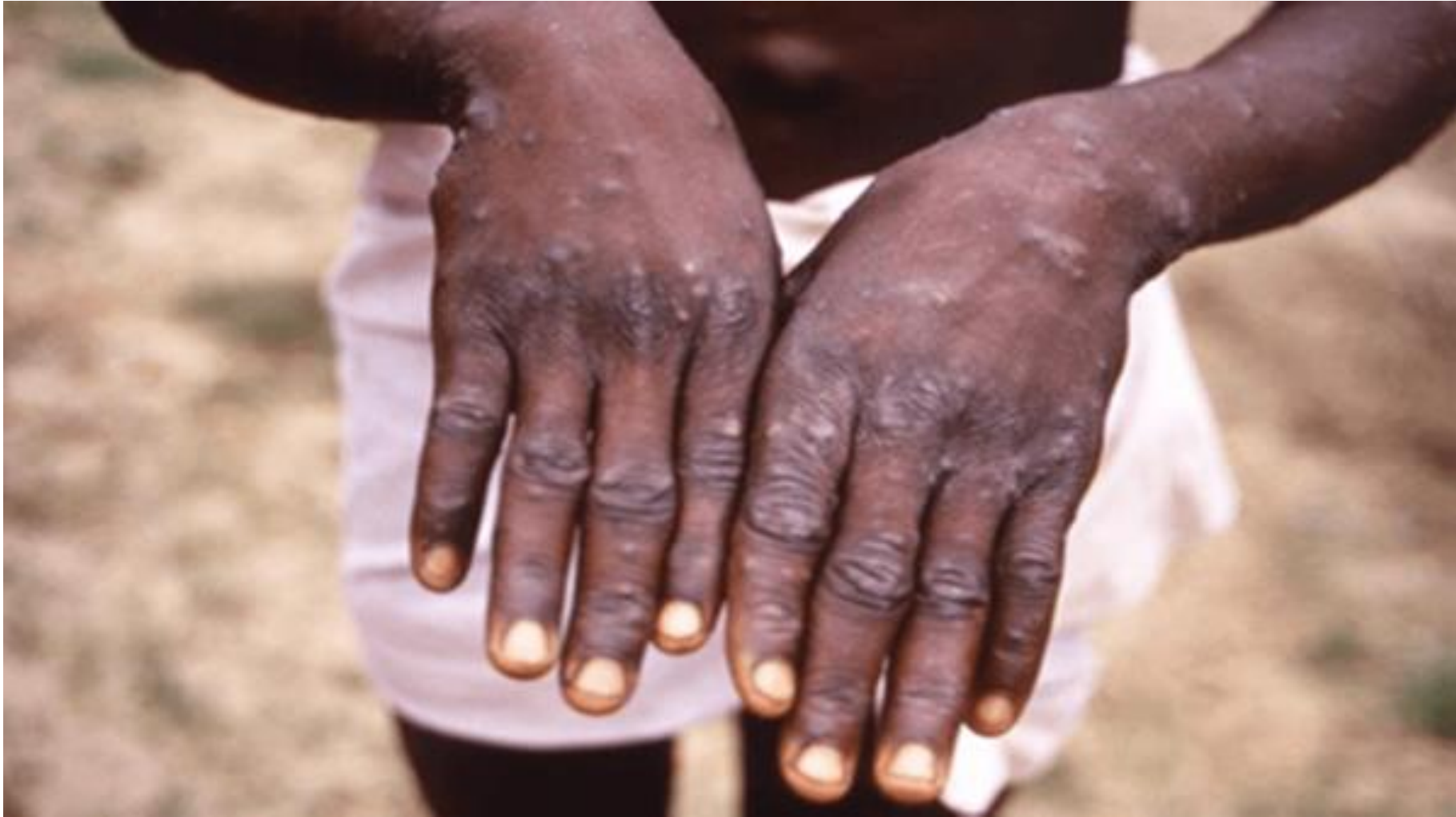Signs and symptoms of Monkeypox

- Usually a self-limited disease with symptoms lasting from 2 to 4 weeks
- Incubation: 7-14 days
- Viral prodrome (0-5 days): Fever, chills, intense headache, myalgia and back pain, **lymphadenopathy***

Signs and Symptoms of Monkeypox

- Skin eruption period (**within 1-3 days** after appearance of fever)
 - **Centrifugal** rash begins on the face and spreads over the body
 - **Face (95%)**, palms and soles (75%) are mostly affected
 - Lesions progress from maculopapules to vesicles, pustules and followed by crust within a period of 10 days to two weeks and the lesions typically progress simultaneously at all parts of body
 - The number of lesions varies from **a few to several thousand**, may also affect oral mucous membranes, genitalia and conjunctivae, as well as the cornea





Monkeypox lesions during the recuperative stage of infection

<https://phil.cdc.gov/Details.aspx?pid=12763>

Signs and symptoms for 34 patients with confirmed monkeypox, United States, 2003

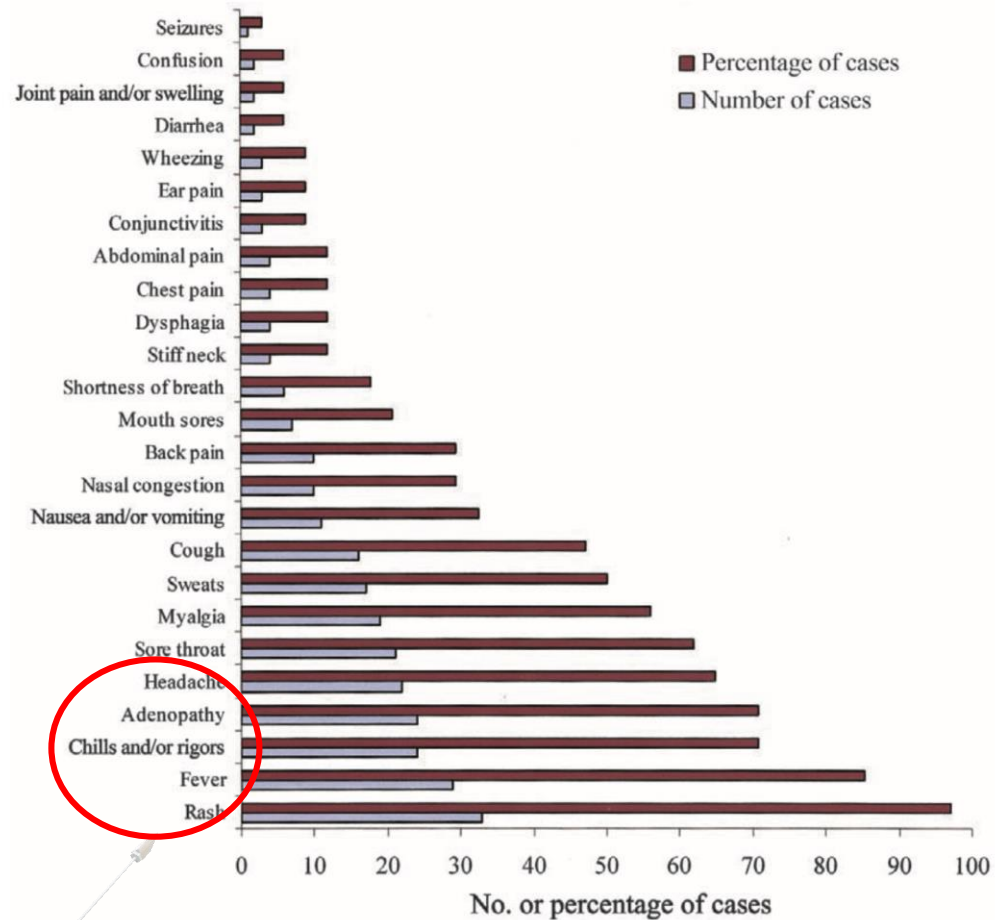


Figure 1. Signs and symptoms for 34 patients with confirmed monkeypox, United States, 2003

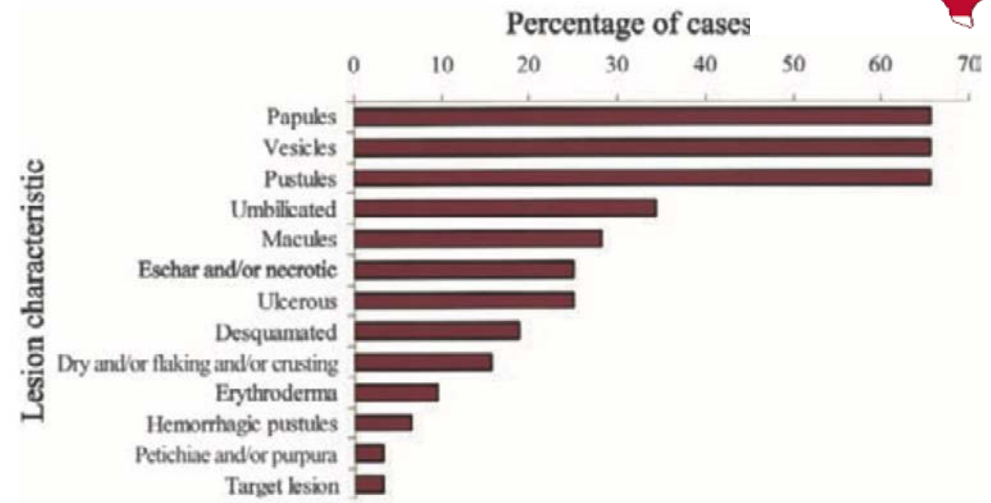
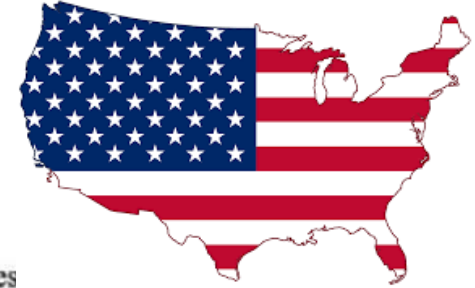

Figure 2. Characteristics of monkeypox rash lesions at the time of examination, United States, 2003.

Laboratory findings of US patients with monkeypox, 2003

Table 5. Timing and magnitude of laboratory findings for US patients with monkeypox.

Laboratory parameter	Normal adult range	All patients		Patients with early results of laboratory tests		Patients with late results of laboratory tests		P ^a
		No. evaluated	Median value (range)	No. evaluated	Median value (range)	No. evaluated	Median value (range)	
WBC count, cells/mm ³	4000–9000	20	7150 (3900–26,800)	11	6200 (3900–17,900)	8	8670 (4780–26,800)	.22
Lymphocytes, %	...	19	26 (14–47)	11	24 (14–44)	7	36 (18–47)	.10
Hematocrit, %	39–49 ^b and 35–45 ^c	20	41 (34.3–52)	11	41 (36–50)	8	42 (35.4–52)	.93
Platelet count, ×10 ⁹ platelets/L	150–400	20	183 (90–369)	11	154 (126–237)	8	216 (90–369)	.09
Sodium level, mmol/L	136–145	19	138 (133–143)	9	137 (135–141)	9	138 (133–141)	1.0
Potassium level, mmol/L	3.5–5.0	19	3.8 (3.2–4.2)	9	3.8 (3.4–4.1)	9	3.9 (3.2–4.2)	.90
Blood urea nitrogen level, mg/dL	10–20	18	9.5 (4–15)	8	9.5 (6–12)	9	10 (4–15)	.85
Creatinine level, mg/dL	<1.5	18	0.8 (0.4–1.1)	9	0.9 (0.1–1.1)	8	0.8 (0.4–0.9)	.31
Calcium level, mmol/L	9.0–10.5	18	9.3 (8.3–10.3)	9	9.3 (8.9–9.9)	8	9.4 (8.3–10.3)	.74
Total bilirubin level, mg/dL	0.3–1.0	17	0.4 (0.1–1.3)	8	0.4 (0.1–0.6)	8	0.5 (0.2–1.3)	.35
AST level, U/L	0–35	16	27.5 (17–95)	8	26 (20–95)	7	38 (17–67)	.82
ALT level, U/L	0–35	17	35 (11–186)	8	30 (11–186)	8	45 (15–90)	.39
ALP level, U/L	40–140	17	94 (30–209)	8	87 (63–145)	8	103 (30–209)	.39
Albumin level, mg/dL	3.5–5.5	16	3.7 (1.1–4.2)	8	3.8 (3.5–4.2)	7	3.7 (1.1–4.0)	.34

NOTE. Early results of laboratory tests were available <6 days after illness onset, and late results were available ≥6 days after illness onset. ALP, alkaline phosphatase; ALT, alanine aminotransferase; AST, aspartate aminotransferase.

^a Comparison of median values of early vs. late results of laboratory tests.

^b For men.

^c For women.

Leukocytosis, elevated transaminase levels, low blood urea nitrogen level, and hypoalbuminemia were common features during illness in this cohort

Another study cohort in the UK

- Review on 7 confirmed monkeypox cases in the UK from 2018- 2021
- 4 acquired infection in Africa; 1 acquired the virus nosocomially: 2 belonged to household cluster

Clinical features and management of human monkeypox: a retrospective observational study in the UK

Hugh Adler, Susan Gould, Paul Hine, Luke B Snell, Waison Wong, Catherine F Houlihan, Jane C Osborne, Tommy Rampling, Mike BJ Beadsworth, Christopher JA Duncan, Jake Dunning, Tom E Fletcher, Ewan R Hunter, Michael Jacobs, Saye H Khoo, William Newsholme, David Porter, Robert J Porter, Libuše Ratscliffé, Matthias L Schmid, Malcolm G Semple, Anne J Tunbridge, Tom Wingfield, Nicholas M Price* on behalf of the NHS England High Consequence Infectious Diseases (Airborne) Network†*

Summary

Background Cases of human monkeypox are rarely seen outside of west and central Africa. There are few data regarding viral kinetics or the duration of viral shedding and no licensed treatments. Two oral drugs, brincidofovir and tecovirimat, have been approved for treatment of smallpox and have demonstrated efficacy against monkeypox in animals. Our aim was to describe the longitudinal clinical course of monkeypox in a high-income setting, coupled with viral dynamics, and any adverse events related to novel antiviral therapies.

Methods In this retrospective observational study, we report the clinical features, longitudinal virological findings, and response to off-label antivirals in seven patients with monkeypox who were diagnosed in the UK between 2018 and 2021, identified through retrospective case-note review. This study included all patients who were managed in dedicated high consequence infectious diseases (HCID) centres in Liverpool, London, and Newcastle, coordinated via a national HCID network.



Summary of clinical course and response to treatment in seven patients with monkeypox

	2018			2019	2021		
	Patient 1	Patient 2	Patient 3	Patient 4	Patient 5	Patient 6	Patient 7
Site of HCID unit	London	Liverpool	Newcastle	London	Liverpool	Liverpool	Liverpool
Age range, years*	30–40	30–40	30–40	40–50	30–40	<2	30–40
Sex	Male	Male	Female	Male	Male	Female	Female
Transmission rank	Isolated	Index	Secondary	Isolated	Index	Secondary	Tertiary
Country of acquisition	Nigeria	Nigeria	UK	Nigeria	Nigeria	UK	UK
Smallpox vaccination history	None	None	MVA six days post-exposure or 12 days pre-illness	None	None	None	None
HIV, hepatitis B, and hepatitis C status	Negative	Negative	Negative	Negative	Negative	Not tested (parents negative)	Negative
Prodrome	Fever and night sweats (2 days)	Fever and groin swelling (4 days)	Coryzal illness (1 day)	Fever and headache (2 days)	None	None	None
Lymphadenopathy	Yes	Yes	No	Yes	Yes	Yes	No
Approximate maximum number of concurrent lesions	150	100	32	100	40	30	10
Distribution of lesions	Face, scalp, trunk, limbs, palms, glans penis, and scrotum	Face, trunk, limbs, palms, soles, and scrotum	Face, trunk, hands (including nail bed), and labia majora	Face, scalp, trunk, limbs, penile shaft, palms, and soles	Face, trunk, limbs, palms, and penile shaft	Face, trunk, arms, and legs	Face, trunk, arms, and hands
Complications of illness	Low mood and emotional lability. Ulcerated inguinal lesion with delayed healing	Deep tissue abscesses, severe pain, and low mood	Conjunctivitis, painful disruption of thumbnail from subungual lesion	Ulcerated inguinal lesion with delayed healing	None	Pruritis and contact dermatitis from cleaning products	Low mood
Specific management of complications	Clinical psychology input	Empiric broad-spectrum antibiotics, abscess drainage, and analgesia (including opiate and neuropathic agents)	Antibacterial eye drops	Empiric azithromycin	Nil specific	Calamine lotion and short course of antibiotics at the onset of dermatitis	Nil specific
Monkeypox viral DNA detected							
Blood	Yes	Yes	Yes	Yes	No	Yes	Yes
Nose or throat swab	Yes	Yes	Yes	Yes	Yes	Yes	Yes
Urine	Yes	Yes	Yes	Yes	No	No	No
Antivirals received	Brincidofovir 200 mg (one dose) orally	Brincidofovir 200 mg (two doses) orally	Brincidofovir 200 mg (two doses) orally	None	None	None	Tecovirimat 600 mg twice daily for 2 weeks orally
Day of illness treatment commenced†	7	6	7	5
Complications of treatment	Transaminitis (peak ALT 331 U/L)	Transaminitis (peak ALT 550 U/L)	Transaminitis (peak ALT 127 U/L), nausea, and abdominal discomfort	None
Duration of hospitalisation with monkeypox, days	26	27	35	39	13	22	10
Outcome of monkeypox infection	Full recovery	Full recovery	Full recovery	Full recovery	Full recovery	Full recovery	Full recovery

HCID=high consequence infectious disease. MVA=modified vaccinia Ankara. ALT=alanine transaminase. *Age ranges rather than exact ages are given for patient anonymity. †Onset of illness was defined as the first identification of skin lesions by the patient or carers.

Table: Summary of the clinical course and response to treatment in seven patients with monkeypox

Skin and soft tissue manifestations of monkeypox

All seven patients had pleiomorphic skin lesions (including papules, vesicles, pustules, umbilicated pustules, ulcerating lesions, and scabs) that were PCR positive for monkeypox virus DNA.

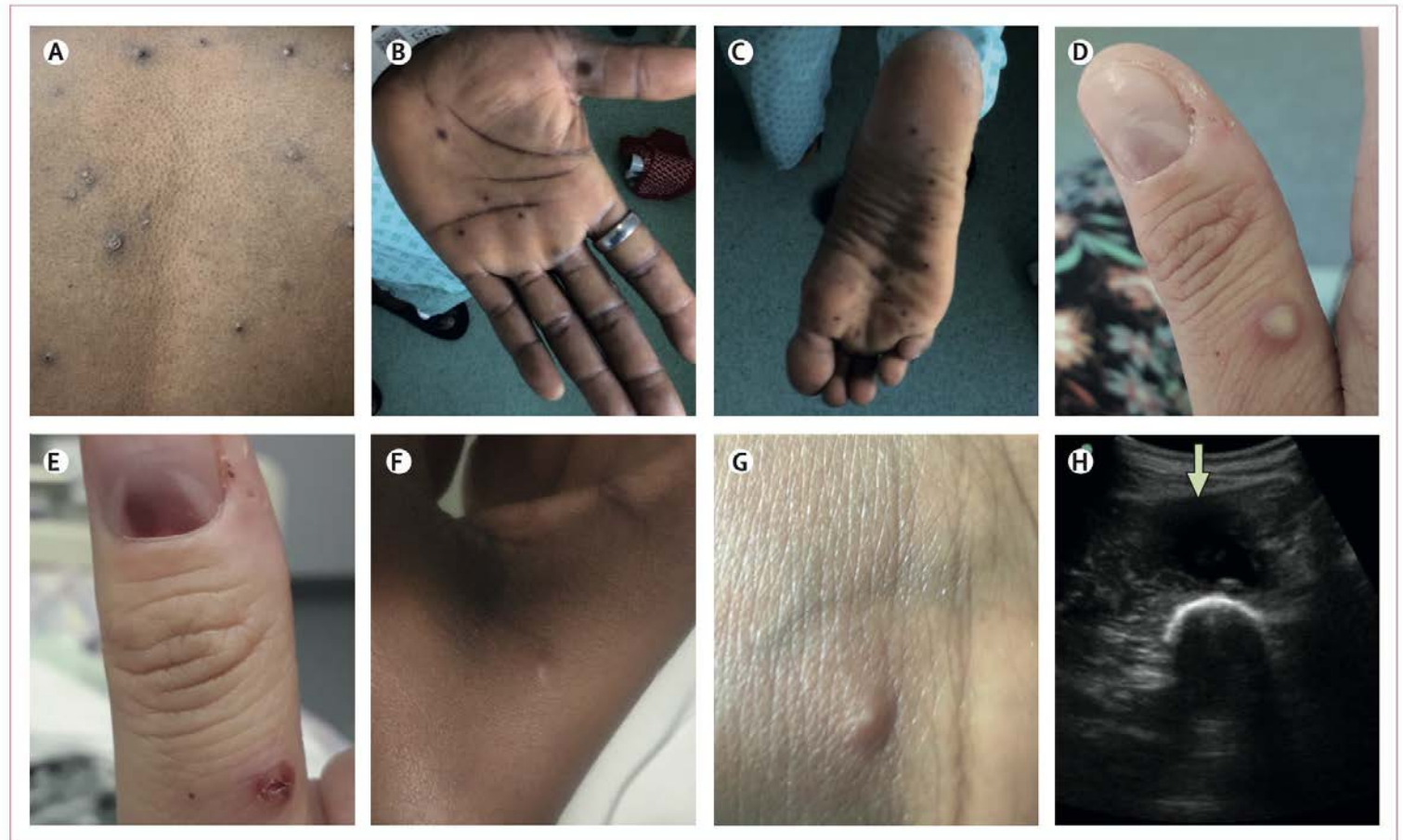

Figure 2: Skin and soft tissue manifestations of monkeypox

Skin and soft tissue features included: (A and D) vesicular or pustular lesions; (B and C) macular lesions involving the palms and soles; (D and E) a sub-ungual lesion; (F and G) more subtle papules and smaller vesicles; (H) and a deep abscess (arrow, image obtained during ultrasound-guided drainage).

Severe cases

- Severe cases occur more commonly among children and are related to the extent of virus exposure, patient health status and nature of complications
- Complications include secondary infections, bronchopneumonia, sepsis, encephalitis, and sight-threatening keratitis

10yo patient
with
complication of
retropharyngeal
abscess

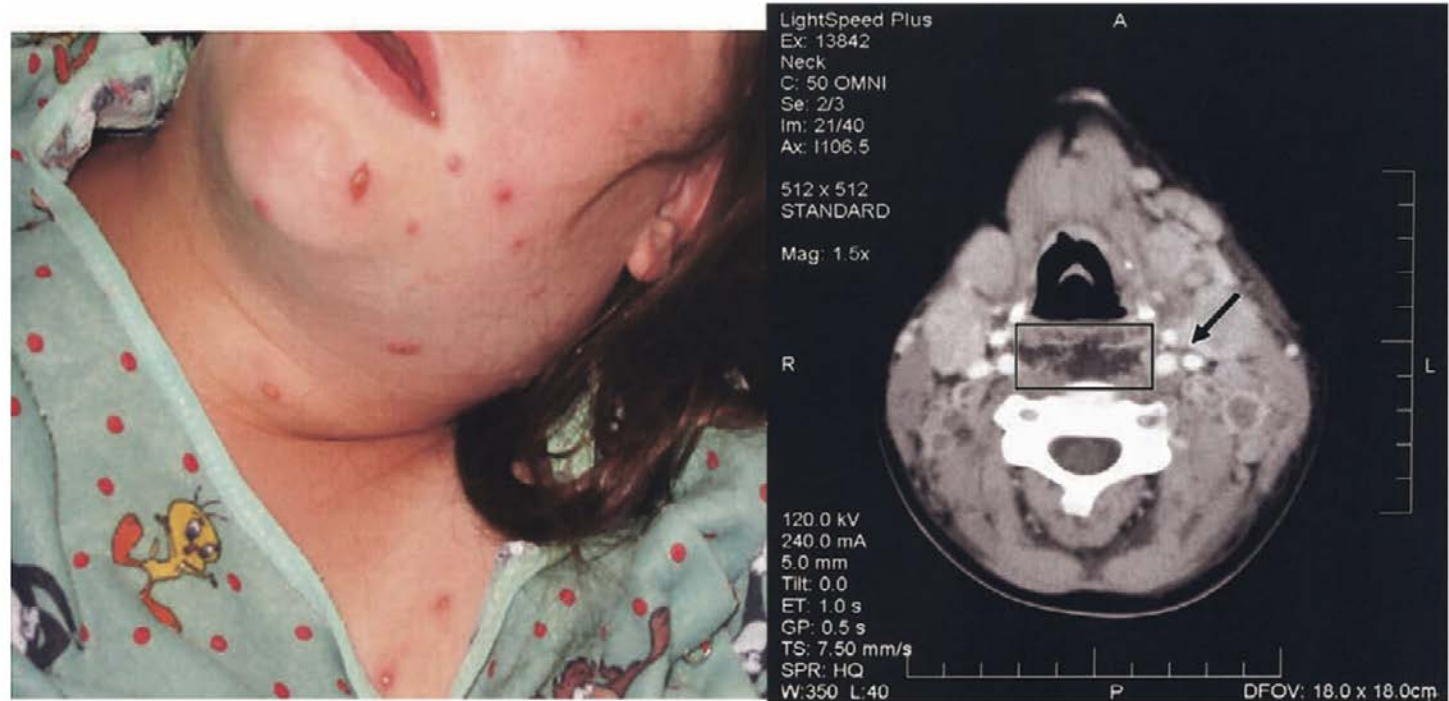
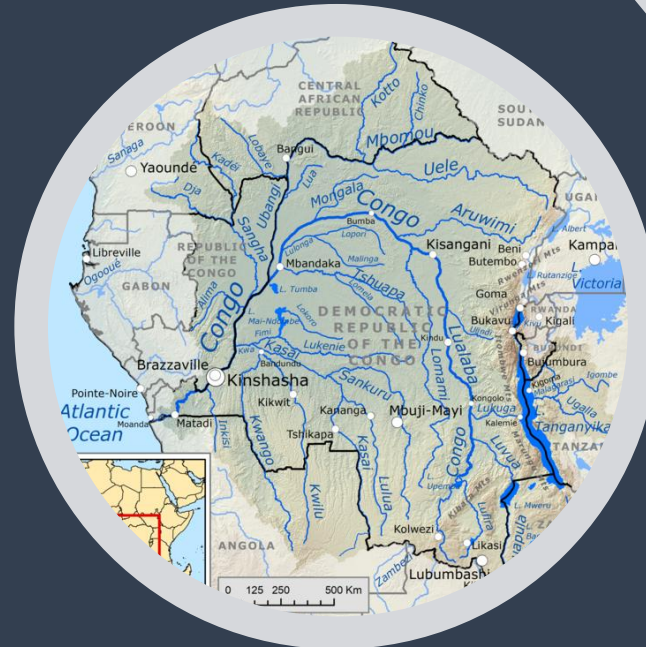

Figure 3. Physical (*left*) and radiographic (*right*) characteristics of monkeypox infection for a girl aged 10 years with a retropharyngeal abscess, tracheal impingement, and cervical lymphadenopathy, United States, 2003.

Case fatality

- Case fatality rates ranging from **1% to 10%** have been reported in outbreaks in the **Congo Basin**, and the virus clade circulating in this region appears to be associated with higher virulence





Case fatality

- The **West African clade**, which is responsible for recent outbreaks in Nigeria, is associated with an overall lower mortality rate consistently less than 3%
- Most reported deaths have occurred in young children and people with HIV

Diagnosis

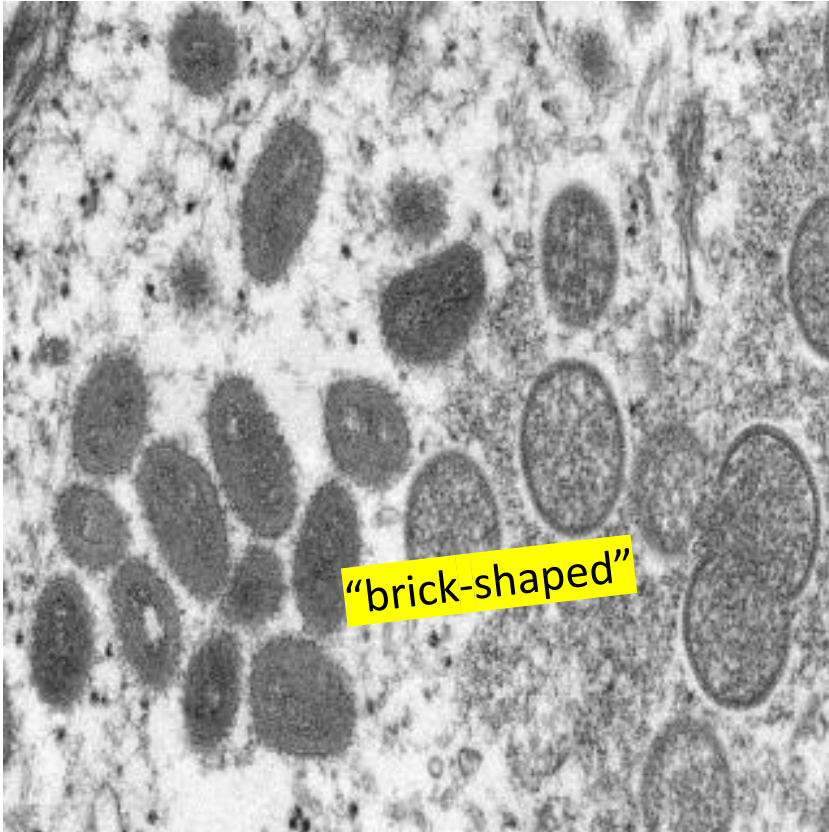
- Specimen should be sent to PHLSB for **RT-PCR** test for monkeypox (TAT<24 hours for negative result)
- Specimen types:
 - **Dry swab** in sterile container
 - AND/ OR
 - **Vesicle fluid** in plain sterile bottle or syringe with needle removed and syringe capped



- For swabs, use sterile polyester or Dacron swab. Do not use wooden swab as it may cause PCR inhibition and false negative results. The swab should be sent dry by putting in a sterile container without viral transport medium

Remark: Prior arrangement should be made with microbiologist before sending the specimen

Electron Microscopy (EM)



Electron microscope image of monkeypox virions from a human skin sample. On the left are mature, oval-shaped virus particles, and on the right are the crescents, and spherical particles of immature virions

Source: <https://phil.cdc.gov/Details.aspx?pid=22664>

Clinical management



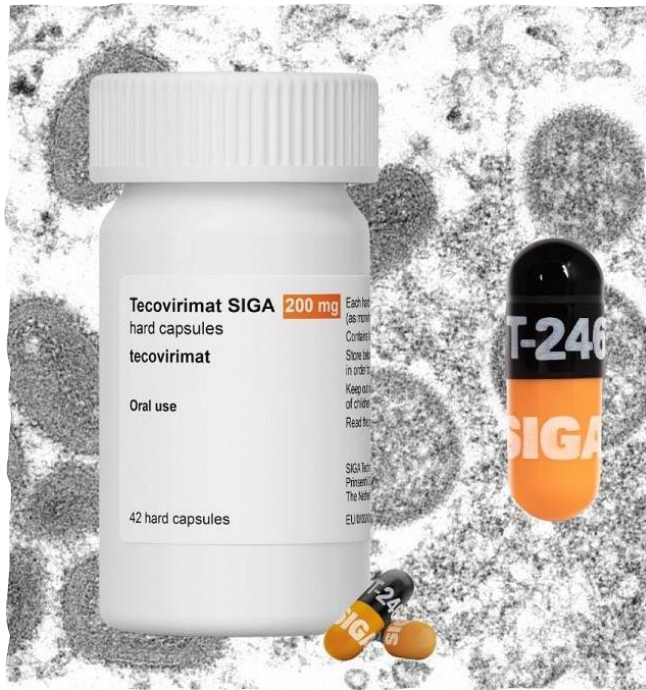Clinical management- Supportive

- Mainstay of treatment is supportive
- Ensure adequate hydration and nutritional status
- Secondary bacterial infections should be treated as indicated
- The current outbreaks as of May 2022 involves the milder West African clade with most cases presented with mild symptoms and recovered with supportive care

Clinical management- Specific Rx

- Several antiviral agents maybe useful for treatment of monkeypox based on their activity against other pox viruses in animal and human studies
 - a) Tecovirimat (ST-246)
 - b) Cidofovir and
 - c) Brincidofovir (CMX001)
- The US CDC considers that smallpox vaccine, cidofovir, tecovirimat, and vaccinia immune globulin (VIG) can be used to control a monkeypox outbreak

Tecovirimat (ST-246)



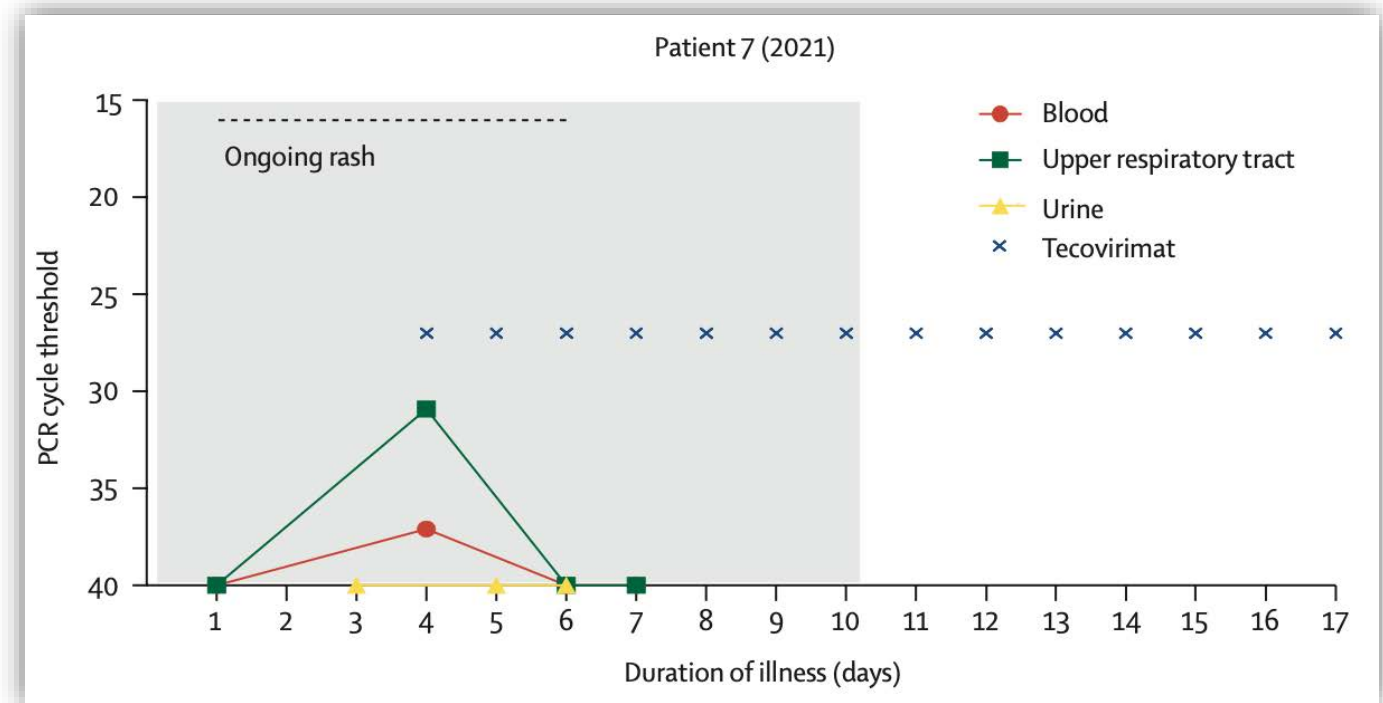
- Tecovirimat works by **interfering with the VP37 protein** on the surface of orthopoxviruses, including smallpox, monkeypox and cowpox.
- **Studies in animals** who had received lethal doses of either monkeypox or rabbitpox viruses showed that treatment with Tecovirimat for 14 days significantly **increased survival rates**.
- According to US CDC, data is **not available** on the **effectiveness** of tecovirimat in treating **human cases** of monkeypox. Human clinical trials indicated the drug was safe and tolerable with only minor side effects.
- Common adverse reactions ($\geq 2\%$): headache, nausea, abdominal pain and vomiting; injection site reactions (IV form)

Tecovirimat (TPOXX™)

- Approved by FDA in 2018 for **smallpox**
- US CDC holds an **[REDACTED]** (EA-IND) for treatment of non-variola orthopoxviruses (including monkeypox) in an outbreak.
- Tecovirimat was also licensed by the European Medical Association (EMA) for monkeypox treatment in 2022
- As of May 19 2022, tecovirimat is approved for both oral and IV administration, thus expanding its potential utility

Tecovirimat use in an UK patient, 2021

- Age 30s, acquired via household contact
- Given **Tecovirimat 600mg BD for 2 weeks** (oral)
- Samples from blood and URI became PCR negative 48 h after commencing Rx
- No new skin lesions developed after 24 h of therapy
- **No adverse effects or complications**, with full recovery





Tecovirimat treatment consideration by US CDC (Under EA-IND protocol)

May be considered for treatment in people with monkeypox

- With **severe disease** (e.g. hemorrhagic disease, confluent lesions, sepsis, encephalitis)
- Who are **at risk of severe disease** (e.g. immunocompromised, pediatric (<8), pregnant, or people with one of more complications)
- With **aberrant infections** involving accidental implantation in eyes, mouth, or other anatomical areas which might constitute a special hazard (e.g. the genitals or anus)

Way forward

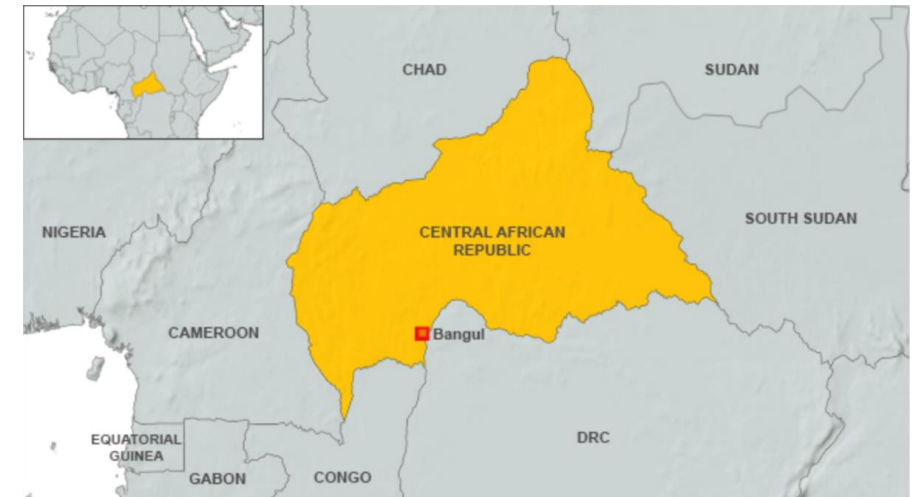

SIGA Announces Collaboration with Oxford University to Support Expanded Access Protocol for Use of TPOXX® (Tecovirimat) To Treat Monkeypox in Central African Republic

July 29, 2021 03:30 ET | Source: SIGA Technologies Inc.

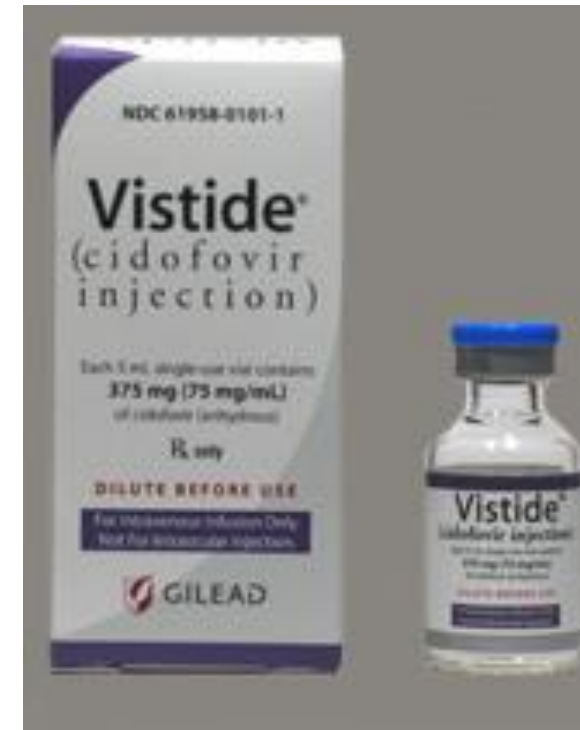NEW YORK, July 29, 2021 (GLOBE NEWSWIRE) -- SIGA Technologies, Inc. (SIGA) (NASDAQ: SIGA), a commercial-stage pharmaceutical company focused on the health security market, today announced that it has entered into a collaboration with Oxford University in the United Kingdom (UK) to provide TPOXX® (tecovirimat) under an expanded access protocol to treat individuals affected by monkeypox in the Central African Republic (CAR). Under the agreement, Oxford University will sponsor the protocol and study in CAR, and SIGA will provide up to 500 courses of TPOXX (tecovirimat) at no cost.

The Institut Pasteur of Bangui ("IPB"), a research foundation established in CAR in 1961, will act as coordinator and be responsible for oversight and conduct of the study in CAR including managing the investigational sites, hosting the clinical trial database and performing the biological testing. The Ministry of Health and Population of CAR ("Ministry") will be responsible for the administration of TPOXX (tecovirimat) to patients with monkeypox infection at the selected investigational sites.



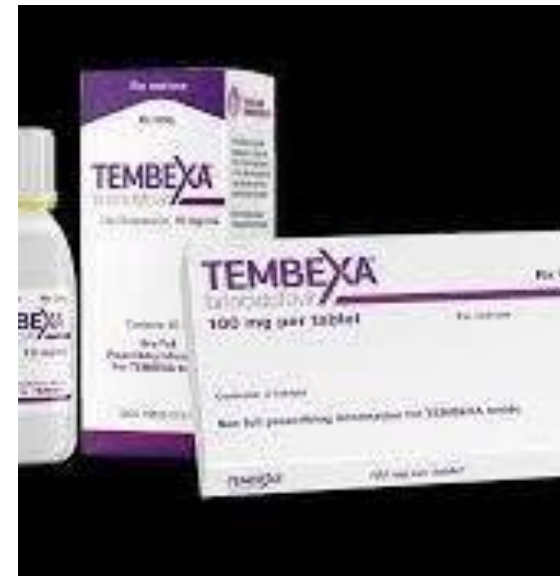Cidofovir

- **Cidofovir** is an intravenous antiviral medication for treatment of cytomegalovirus (CMV) retinitis in patients with AIDS and transplant recipients. Cidofovir also demonstrates in vitro activity against a number of DNA viruses including herpes viruses, adenoviruses, polyomaviruses, papillomaviruses and poxvirus.
- CDC holds an EA-IND that allows for the use of Cidofovir for the treatment of [REDACTED].
- Cidofovir is registered in Hong Kong.



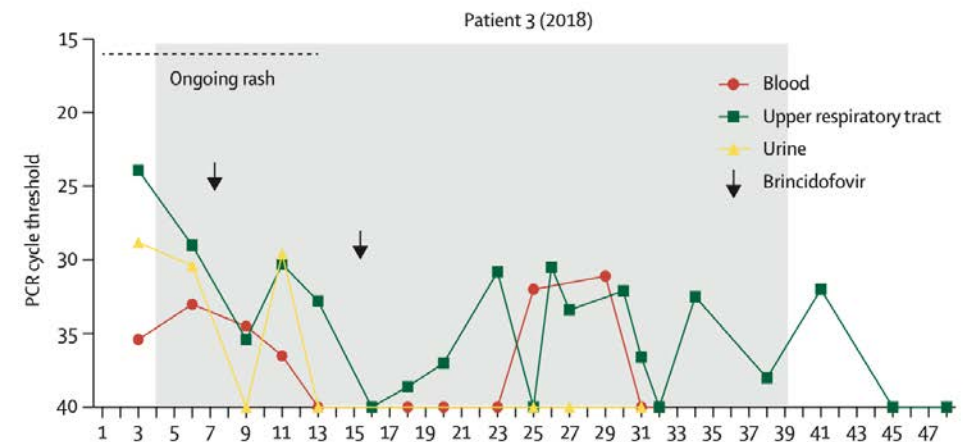
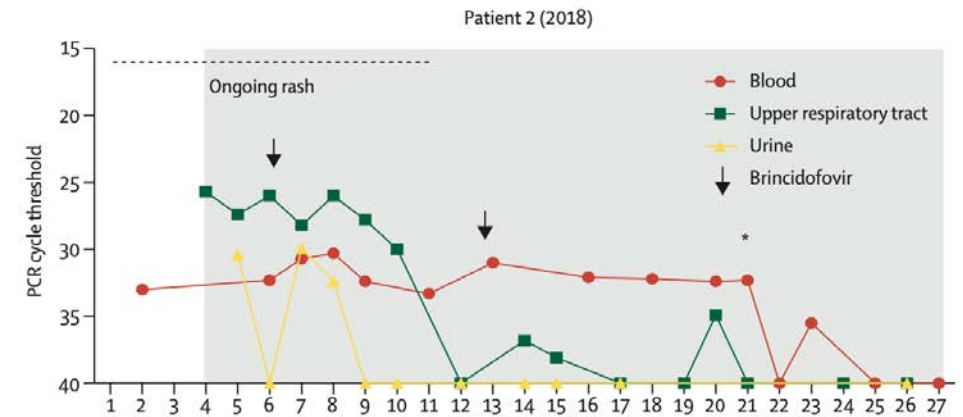
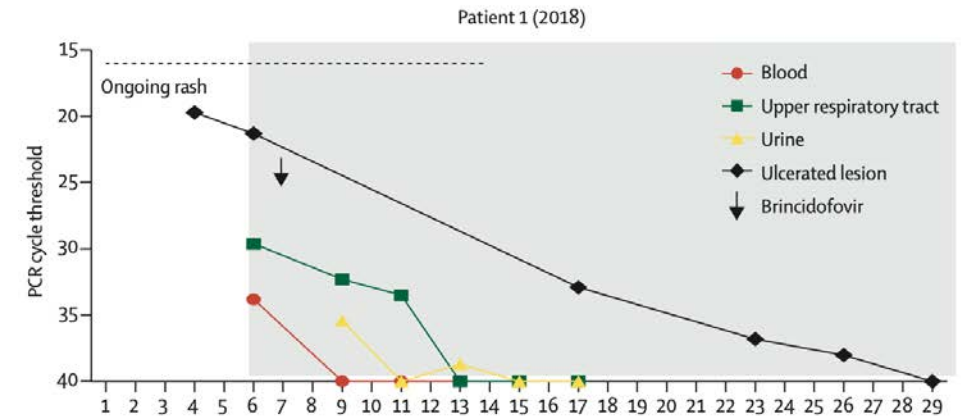
Brincidofovir (CMX001)

- **Brincidofovir** is an oral acyclic nucleoside phosphonate that is converted intracellularly to [cidofovir](#); unlike cidofovir, brincidofovir is not concentrated in the renal proximal tubules and is therefore not nephrotoxic.
- Brincidofovir was approved in the US for treatment of smallpox in adults and children including neonates in June 2021
- Dosing (adult): 200mg once weekly for 2 doses oral
- Brincidofovir is not registered in Hong Kong



Clinical outcome of 3 patients treated with brincidofovir in the UK

- Commenced approximately 7 days post onset of rash
- Oral 200mg once a week x 3 doses
- **No consistent association** between doses of brincidofovir and clinical or virological parameters, although patient 2 and 3 demonstrated transient reductions in URT viral load around the time of second doses
- All 3 patients had rise in ALT and did not complete full course of treatment
- All patients made a full recovery



Raised ALT after Brincidofovir

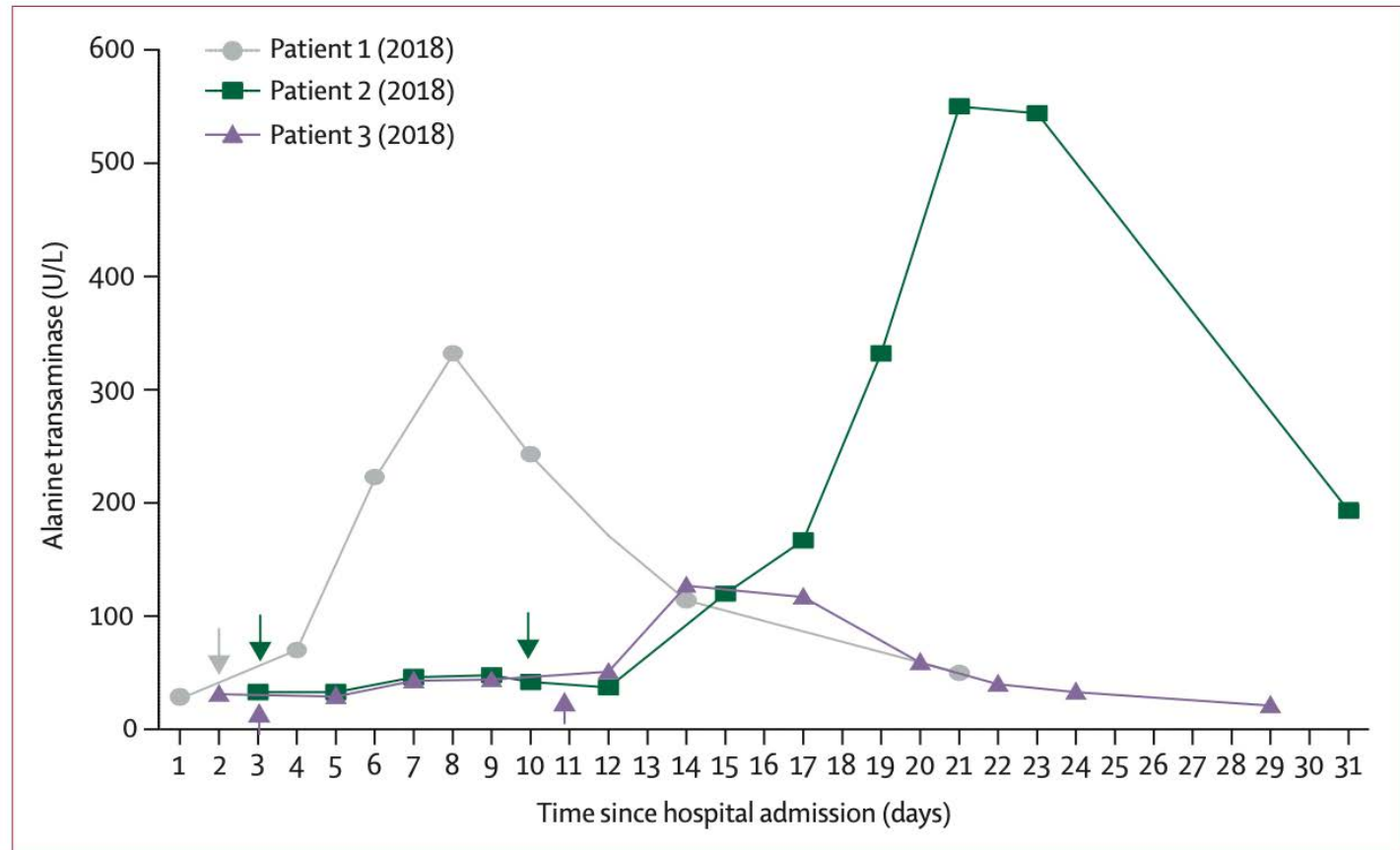


Figure 3: Alanine transaminase values of the three patients who received therapy with brincidofovir
Doses of brincidofovir are denoted by arrows, with the colour of the arrow corresponding with the colour of the relevant patient's alanine transaminase graph. Normal range of alanine transaminase is less than 30 U/L.

Vaccinia Immune Globulin Intravenous (VIGIV)

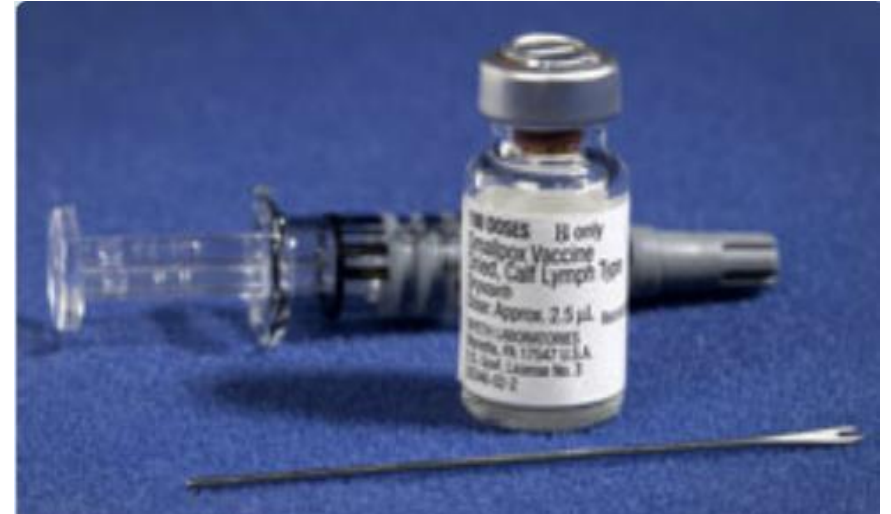- VIGIV is licensed by FDA for the treatment of complications due to vaccinia vaccinations and severe vaccinia infections
- CDC holds an EA-IND that allows the use of VIGIV for treatment of orthopoxviruses (including monkeypox) in an outbreak
- Not available in Hong Kong



Vaccination

Vaccination

- Currently there is no registered specific vaccine for monkeypox available in Hong Kong
- According to WHO, vaccination against smallpox was demonstrated through several observational studies to be about **85% effective** in preventing monkeypox.
- In US, Smallpox vaccine is not currently available to the general public. In the event of another outbreak of monkeypox in the U.S., CDC will establish guidelines explaining who should be vaccinated



JYNNEOS- Smallpox and Monkeypox Vaccine

- **Jynneos** (also known as Imvamune or Imvanex) is a vaccine based on a modified attenuated vaccinia virus (Ankara strain) approved for the **prevention of monkeypox and smallpox by FDA**
- It is a live, non-replicating vaccine for adults 18 years of age and older; administered in **two doses given four weeks apart**
- The effectiveness of Jynneos for the prevention of monkeypox disease is inferred from the antibody responses in the smallpox clinical study participants and from studies in non-human primates that showed protection of animals vaccinated with Jynneos who were exposed to the monkeypox virus.
- Most common side effects: pain, redness, swelling, itching, firmness at the injection site, muscle pain, headache and fatigue.

ACAM2000- Live vaccinia vaccine

- **ACAM2000** contains a live vaccinia virus, which is licensed in the US for immunization in people who are at least 18 years old and at high risk for **smallpox infection**.
- Administered as a single dose
- The vaccine does not contain variola virus and cannot cause smallpox. It contains vaccinia virus, which belongs to the poxvirus family, genus *Orthopoxvirus*. The vaccinia virus may cause rash, fever, and head and body aches.

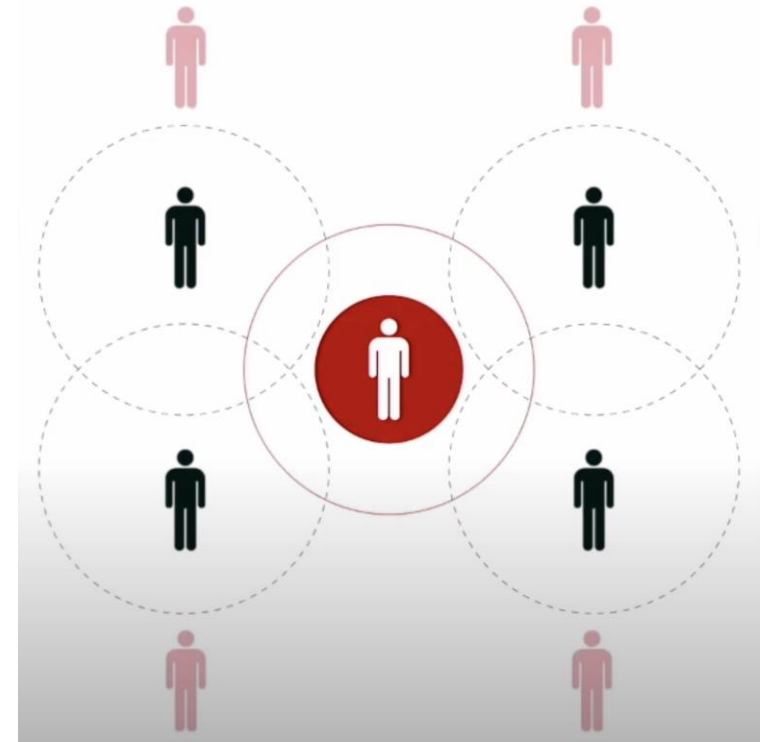
Vaccination strategies

- **Ring vaccination?**

- Both vaccines may be used as post-exposure prophylaxis (PEP) if necessary.
- The sooner an exposed person gets the vaccine, the better. US CDC recommends that the vaccine be given [redacted] from the date of exposure in order to prevent onset of the disease.
- If given between 4–14 days after the date of exposure, vaccination may reduce the symptoms of disease, but may not prevent the disease.


- **Healthcare personnel?**

- 2015 ACIP recommendation advise routine vaccination of laboratory personnel who directly handle cultures of, or animals infected with poxviruses



Credit: John Johnson

Referring back to the questions earlier on..



- How should we recognize the symptoms and signs of monkeypox?
 - Vigilant about returned travellers with viral symptoms + rash + lymphadenopathy*
- Is monkeypox a lethal disease?
 - <3% for the West African clade, usually a self-limiting disease with supportive Rx. Watch out for at risk cases e.g. immunocompromised, paediatrics
- Are there specific antiviral treatments?
 - Limited clinical data. Currently cidofovir is the only available antiviral in HK. There is plan to stockpile other antivirals e.g. tecovirimat
- Is vaccine available?
 - JYNNEOS and ACAM2000 vaccines are FDA approved vaccines against smallpox +/- monkeypox
 - Both are not available in HK at the moment



thank you